

SHORT COMMUNICATION

Osteological malformation in the tree frog *Hypsiboas geographicus* (Anura: Hylidae)

Pedro L. V. Peloso

Museu Paraense Emílio Goeldi, CZO, Av. Perimetral, 1901, Terra Firme, 66077-830, Belém, Pará, Brazil. E-mail: pedropeloso@gmail.com.

Division of Vertebrate Zoology (Herpetology), American Museum of Natural History, Central Park West at 79th Street, New York, NY, 10024, USA.

Keywords: Cophomantinae, CT-scan, Map Tree Frog, sacral structure.

Palavras-chave: Cophomantinae, estrutura sacral, perereca, tomografia computadorizada.

Amphibian morphological malformations are common—the causes of deformities are various and include both genetic and environmental factors (e.g., infections, parasites, pesticides or heavy metal poisoning) (Ouellet 2000). The rates of morphological abnormalities normally range from 0–6% (Dubois 1979, Read and Tyler 1994, Ouellet 2000, Kovalenko and Kruzhkova 2013). However, in extreme cases (i.e., factors related to disease or poison), the percentage of abnormal frogs in populations of the same species has been reported to be as high as 69% (Ouellet *et al.* 1997, Johnson *et al.* 2001).

Abnormalities involving the posterior vertebrae and sacral structure of anurans have been reported and thoroughly described in the literature (Kovalenko 1994, Kovalenko and Daniletskaya 1994, Kovalenko and Kruzhkova

2013). Frogs and toads normally have only one pair of sacral diapophyses on Vertebra IX (Kovalenko and Kruzhkova 2013); reported abnormalities include absence of sacral diapophyses, an increased number of sacral diapophyses (i.e., more than one pair present), and variation in the positions of the sacral diapophyses. Thus, the diapophyses may be paired on Vertebra VIII (presacral) or X (postsacral), or with one diapophysis asymmetrically displaced with respect to its contralateral diapophysis on adjacent vertebrae (Kovalenko and Kruzhkova 2013).


Here, I report on similar malformations in the sacral elements of two Map Tree Frogs, *Hypsiboas geographicus* (Spix, 1824). The specimens come from widely disjunct populations (AMNH 76172: Amazonas, Brazil, collected in 1965; and AMNH 91748: Loreto, Peru; collected in 1970) and the deformities were noted in CT scans. Whole frogs were scanned in a GE Phoenix Vtome Xs Micro Computed Tomography at the Microscopy and

Received 23 September 2015
Accepted 17 February 2016
Distributed June 2016

Image Facility at the American Museum of Natural History (MIF / AMNH). Scans were performed at resolutions varying from 15–60 nanometers, with x-ray operating at 100–200 kV and 80–160 mA. Three-dimensional reconstructions of the individual x-rays, and image 3D visualizations were done in VGStudio MAX version 2.2 (Volume Graphics, Heidelberg, Germany) at the Microscopy and Imaging Facility at the American Museum of Natural History.

In both specimens of *H. geographicus*, one sacral diapophysis is present Presacral Vertebra XIII in place of the usual transverse process, which seems to have been displaced posteriorly to the sacrum (Vertebra IX: Figure 1). The transverse processes misplaced in the sacrum are acutely projected posteriorly in both frogs, and is less developed in the specimen from Brazil (AMNH 76172) than in the specimen from Peru (AMNH 91748). In both cases, the malformation is unilateral, with the contralateral part of the column seemingly normal (Figure 1). This condition was described by Kovalenko and Kruzhkova (2013). Close examination of the morphology of the presacral and sacral centra in both individuals reveals that the vertebral elements have normal morphology. The asymmetrical displacement of diapophyses doubtless reflects imperfect development in both specimens.

Several types of limb and vertebral malformations may impair the mobility of anurans. I do not know whether either of these frogs was capable of normal locomotion. However, the fact that both individuals described here are mature, reproductively active adults suggests that the condition did not hinder metamorphosis and normal growth. Moreover, the geographical and chronological separation of these two frogs suggest that this malformation may be more common than thought in the taxon—a speculation that could only be confirmed by a thorough survey of the sacral structure in *Hypsiboas geographicus*.

Acknowledgments.—I thank the staff at the American Museum of Natural History's Microscopy and Imaging Facility (Henry Towbin and Morgan Hill) for help with acquiring and processing CT images. My research is supported by Conselho Nacional de Desenvolvimento Científico e Tecnológico (CNPq, BJT: research grant number 400252/2014-7, fellowship number 313680/2014-0). 

References

- Dubois, A. 1979. Anomalies and mutations in natural populations of the *Rana "esculenta"* complex (Amphibia, Anura). *Mitteilungen aus dem Museum für Naturkunde in Berlin, Zoologische Reihe* 55: 59–87.
- Johnson, P. T. J., K. B. Lunde, E. G. Ritchie, J. K. Reaser, and A. E. Launer. 2001. Morphological abnormality patterns in a California amphibian community. *Herpetologica* 57: 336–352.
- Kovalenko, E. E. 1994. The compound sacrum in individual variability of common platanna (*Xenopus laevis*). *Russian Journal of Herpetology* 1: 172–178.
- Kovalenko, E. E. and S. E. Danilevskaya. 1994. On unique forms of anomalous sacral structure in tailless amphibians. *Russian Journal of Herpetology* 1: 30–36.
- Kovalenko, E. E. and Y. I. Kruzhkova. 2013. Individual variation in the development of the common toad, *Bufo bufo* (Anura, Bufonidae): 2. Diagnostic characters of the axial skeleton. *Russian Journal of Developmental Biology* 44: 180–193.
- Ouellet, M. 2000. Amphibian deformities: current state of knowledge. Pp. 617–661 in D. W. Sparling, G. Linder, and C. A. Bishop (eds.), *Ecotoxicology of Amphibians and Reptiles*. Pensacola. Society of Environmental Toxicology and Chemistry (SETAC) Press.
- Ouellet, M., J. Bonin, J. Rodrigues, J. L. DesGranges, and S. Lair. 1997. Hindlimb deformities (ectromelia, ectrodactyly) in free-living anurans from agricultural habitats. *Journal of Wildlife Diseases* 33: 95–104.
- Read, J. L. and M. J. Tyler. 1994. Natural levels of abnormalities in the thrilling frog (*Neobatrachus centralis*) at the olympic dam mine. *Bulletin of Environmental Contamination and Toxicology* 53: 25–31.

Editor: Jaime Bertolucci

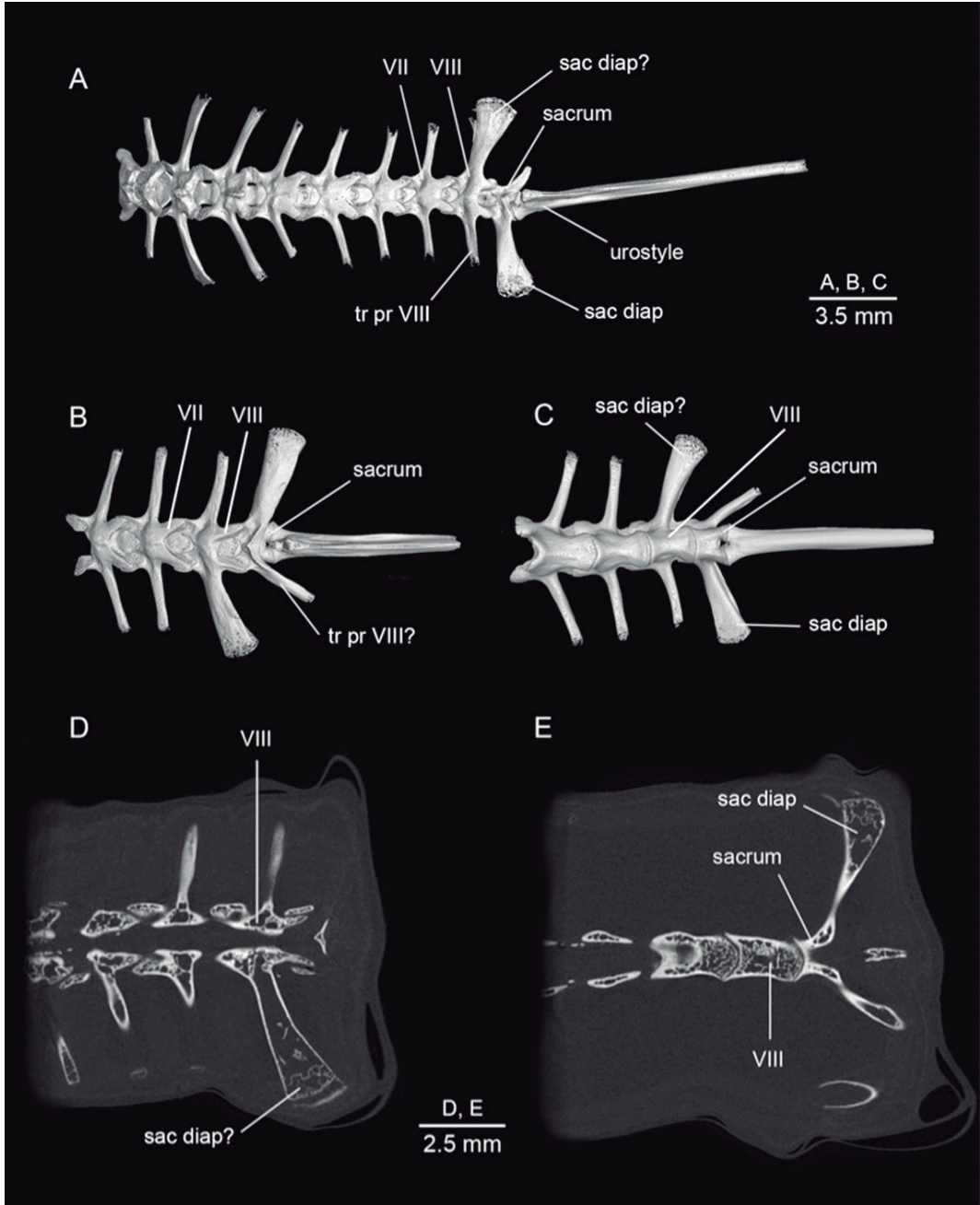


Figure 1. Computed tomography (CT) images of two specimens of *Hypsiboas geographicus* (A: AMNH 76172; B–E: AMNH 91748) showing malformation in the sacral region. (A) Dorsal view of complete vertebral column of AMNH 76172. (B, D, E) dorsal and (C) ventral views of posterior section of the vertebral column in AMNH 91748. Abbreviations: sac diap = sacral diapophysis; tr pr = transverse process; VII = presacral vertebrae number VII; VIII = presacral vertebrae number VIII.